

# Birt–Hogg–Dubé Syndrome

Abdulmonam Ali, Naga Srinivas Sirikonda

Department of Pulmonary and Critical Care, Good Samaritan Hospital, SSM Health, Mount Vernon, Illinois, USA

## Abstract

Cystic lung diseases have a broad differential diagnosis. Accurate diagnosis can make a significant difference in the management approach, as it is highly disease specific. Unique imaging and clinical features can provide crucial clues that help clinicians distinguish various etiologies. Birth-Hogg-Dubé syndrome is a cystic lung disease with extra pulmonary manifestations. Managements involves solid organ cancer screening and hence accurate diagnosis is vital.

**Keywords:** Cystic lung disease, fibrofolliculomas, folliculin gene, lung nodules, pneumothorax, polyps, renal cancer, thin-walled cysts

## INTRODUCTION

Cystic lung diseases have a broad differential diagnosis and achieving an accurate diagnosis can make a significant difference in the management approach, as these are highly disease specific. Unique imaging and clinical features can provide crucial clues that help clinicians distinguish various etiologies.

## CASE REPORT

A 67-year-old nonsmoker female referred by her primary care physician to the pulmonary clinic for incidental abnormal lung findings seen on computed tomography (CT) scan of the abdomen performed for the evaluation of abdominal pain. CT abdomen showed multiple small pulmonary nodules ranging in diameter from 3 to 5 mm along with thin-walled cysts ranging in diameter from 0.5 mm to 2 cm. A full CT chest was obtained, and it showed numerous bilateral round thin-walled cysts predominantly in the lower lobes, mostly subpleural and paramediastinal in a location with multiple tiny lung nodules of 5 mm or less in diameter [Figure 1a and b]. There was no mediastinal or hilar lymphadenopathy, and no other abnormal findings seen on the CT chest.

Reviewing her CT abdomen and pelvis, there were no renal masses or colonic lesions seen.

The patient denied any significant pulmonary symptoms and also denied any prior personal history of pneumothorax. However, she reported family history of recurrent

pneumothorax in her elder brother. She was not aware of any other family history of renal or colonic tumors. Physical examination was relevant for multiple, dome-shaped, flesh-colored skin papules consistent with fibrofolliculomas on the face and neck [Figure 2].

Pulmonary function test demonstrated overall very mild restrictive with slightly reduced total lung capacity but normal residual volume and diffusion capacity.

Her last colonoscopy was 15 years ago. The patient was referred to a gastroenterologist for colonoscopy, and she had a few benign polyps removed, but otherwise, her colonoscopy was normal.

## DISCUSSION

The constellation of the patient's history and clinical findings are highly suggestive of Birt–Hogg–Dubé syndrome (BHDS). Although there is a diagnostic criterion proposed for BHDS, the diagnosis is still based on detailed history and clinical examination findings. Menko *et al.* suggested the following diagnostic criteria for BHDS.<sup>[1]</sup>

### Major criteria

- At least five fibrofolliculomas or trichodiscomas, at least one histologically confirmed, of adult onset

**Address for correspondence:** Abdulmonam Ali, MD,  
SSM Health, Good Samaritan Hospital,  
1 Good Samaritan Way, Mount Vernon IL 62864  
E-mail: [abdulmonam2008@yahoo.com](mailto:abdulmonam2008@yahoo.com)

This is an open access journal, and articles are distributed under the terms of the Creative Commons Attribution-NonCommercial-ShareAlike 4.0 License, which allows others to remix, tweak, and build upon the work non-commercially, as long as appropriate credit is given and the new creations are licensed under the identical terms.

**For reprints contact:** [reprints@medknow.com](mailto:reprints@medknow.com)

**How to cite this article:** Ali A, Sirikonda NS. Birt–Hogg–Dubé syndrome. Indian J Respir Care 2020;9:103-5.

**Received:** 25-04-2019

**Revised:** 14-05-2019

**Accepted:** 15-07-2019

**Published:** 08-01-2020

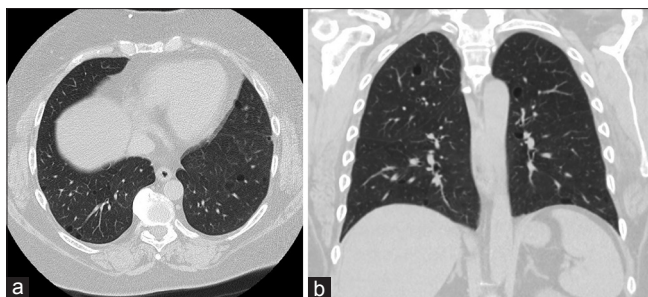
### Access this article online

#### Quick Response Code:



**Website:**  
[www.ijrconline.org](http://www.ijrconline.org)

**DOI:**  
10.4103/ijrc.ijrc\_14\_19



**Figure 1:** (a) Computed tomography chest axial view showing thin-walled cysts predominantly subpleural and lower lobes (b) computed tomography chest coronal view showing bilateral thin-walled cysts

- Pathogenic folliculin (FLCN) germline mutation.

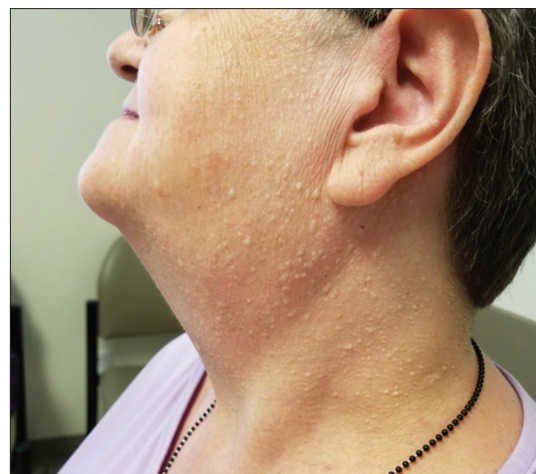### Minor criteria

- Multiple lung cysts: bilateral basally located lung cysts with no other apparent cause, with or without spontaneous primary pneumothorax
- Renal cancer: early-onset (<50 years) or multifocal or bilateral renal cancer or renal cancer of mixed chromophobe and oncocytic histology
- A first-degree relative with BHDS.

The patient should fulfill at least 1 major criterion or 2 minor criteria for diagnosis. Our patient has 1 major criterion as she had more than five fibrofolliculomas, but she declined skin biopsy as her lesions were on the face. Genetic testing was offered to our patient, but unfortunately, she was not interested in the further workup. However, she also met two minor criteria, including the presence of multiple lung cysts as well as a first-degree relative who had a history of recurrent pneumothorax which is retrospectively attributed to undiagnosed BHDS.

The other differential diagnoses for multiple lung cysts associated with lung nodules include lymphangiomyomatosis (LAM), pulmonary Langerhans cell histiocytosis (PLCH), lymphoid interstitial pneumonia (LIP), light-chain deposition disease (LCDD), and amyloidosis. LAM usually occurs in young women of child-bearing age. PLCH occurs in smokers. LIP is associated with connective tissue diseases, HIV, and common variable immunodeficiency. Amyloidosis is associated with Sjögren's syndrome, lymphoproliferative disease, or mucosa-associated lymphoid tissue lymphoma. LCDD is associated with monoclonal immunoglobulin LCDDs such as multiple myeloma or macroglobulinemia.<sup>[2]</sup>

BHDS was first described in 1977, it is inherited as an autosomal dominant condition and is caused by germ line mutations in the FLCN tumor suppressor gene on chromosome 17p11.2. This gene is expressed in many normal tissues, including the skin, kidneys, stromal cells, and lungs.<sup>[3]</sup> Hence, the clinical manifestations of this syndrome may include the development of fibrofolliculomas, trichodiscomas, and acrochordons of the face, neck, and upper trunk.<sup>[4]</sup> Other organ manifestations



**Figure 2:** Face and neck showing multiple, dome-shaped, flesh-colored skin papules consistent with fibrofolliculomas

include increased risk of lung cysts, pulmonary nodules, spontaneous pneumothorax, and renal carcinomas.<sup>[5]</sup> There are also reports of increased risk of colorectal polyps and cancers,<sup>[6]</sup> although other studies have found no statistically significant increase in the risk for development of colon polyps or colon carcinomas.<sup>[7]</sup> BHDS patients are at least nine fold more likely to develop renal tumors compared to normal population and are at least 30 fold more likely risk to develop a spontaneous pneumothorax.<sup>[7]</sup> The risk of renal cancers in such patient is directly proportional to their age and more common in males. Multifocal or bilateral renal tumors are well documented in the syndrome compared to normal population. On the other hand, the risk of pneumothorax is inversely proportional to age.<sup>[7]</sup>

Although the syndrome causes multiple lung cysts with increased risk of recurrent pneumothoraces, reviewing literature, there is currently no evidence to suggest, it can affect the pulmonary function *per se*. Our patient has mild restrictive pattern which is likely extraparenchymal and attributed to her weight (her body mass index was 31.3 kg/m<sup>2</sup>) rather than to her small pulmonary cystic lesions.

There are no clear guidelines for renal cancer screening in patients with BHDS; however, it is recommended to screen those patients with CT, magnetic resonance imaging, or renal ultrasound at the time of diagnosis and at least once every 3 years thereafter. Tumors <3 cm can be monitored, whereas tumors >3 cm are treated with nephron-sparing surgery, including partial nephrectomy.<sup>[8]</sup>

This case illustrates the importance of carefully interpreting the radiological results in correlation with the history and clinical findings. Although BHDS can be easily diagnosed, overall it remains probably the underdiagnosed condition. Practicing physicians should be aware about such rare disease entity as the clinical implications are not only limited for avoiding unnecessary workup or invasive procedures but also to help plan surveillance and screening process for this group of patients that can save lives.

### Declaration of patient consent

The authors certify that they have obtained all appropriate patient consent forms. In the form the patient(s) has/have given his/her/their consent for his/her/their images and other clinical information to be reported in the journal. The patients understand that their names and initials will not be published and due efforts will be made to conceal their identity, but anonymity cannot be guaranteed.

### Financial support and sponsorship

Nil.

### Conflicts of interest

There are no conflicts of interest.

### REFERENCES

1. Menko FH, van Steensel MA, Giraud S, Friis-Hansen L, Richard S, Ungari S, *et al.* Birt-hogg-dubé syndrome: Diagnosis and management. *Lancet Oncol* 2009;10:1199-206.
2. Raoof S, Bondalapati P, Vydyula R, Ryu JH, Gupta N, Raoof S, *et al.* Cystic lung diseases: Algorithmic approach. *Chest* 2016;150:945-65.
3. Warren MB, Torres-Cabala CA, Turner ML, Merino MJ, Matrosova VY, Nickerson ML, *et al.* Expression of Birt-Hogg-Dubé gene mRNA in normal and neoplastic human tissues. *Mod Pathol* 2004;17:998-1011.
4. Birt AR, Hogg GR, Dubé WJ. Hereditary multiple fibrofolliculomas with trichodiscomas and acrochordons. *Arch Dermatol* 1977;113:1674-7.
5. Schmidt LS. Birt-Hogg-Dubé syndrome, a genodermatosis that increases risk for renal carcinoma. *Curr Mol Med* 2004;4:877-85.
6. Kahnoski K, Khoo SK, Nassif NT, Chen J, Lobo GP, Segelov E, *et al.* Alterations of the Birt-Hogg-Dubé gene (BHD) in sporadic colorectal tumours. *J Med Genet* 2003;40:511-5.
7. Zbar B, Alvord WG, Glenn G, Turner M, Pavlovich CP, Schmidt L, *et al.* Risk of renal and colonic neoplasms and spontaneous pneumothorax in the Birt-Hogg-Dubé syndrome. *Cancer Epidemiol Biomarkers Prev* 2002;11:393-400.
8. Pavlovich CP, Walther MM, Eyler RA, Hewitt SM, Zbar B, Linehan WM, *et al.* Renal tumors in the Birt-Hogg-Dubé syndrome. *Am J Surg Pathol* 2002;26:1542-52.